



Carriere® Distalizer™ and Invisalign® Combo for Class II Treatment

Dr. Clark D. Colville

Carriere Distalizer and Invisalign Combo

A distalization appliance that has proven effective in conjunction with Invisalign® treatment for Class II patients is the Carriere Distalizer.¹ The Carriere Distalizer is a simple appliance to measure and place, in addition to being esthetic, and very efficient. This appliance distalizes the maxillary buccal segments en masse, using moderately heavy Class II elastics which are worn from the appliance to a lower arch, typically stabilized with the fixed lower lingual arch. Elastics are worn in conjunction with the appliance between 3 and 4.5 months. The primary effect of the Class II elastics is the significant sagittal change in the cuspid position with minimal distal crown tipping, as evidenced by the widened periodontal ligament that extends the entire length of the root radiographically. Mild maxillary distal molar rotation also occurs along with distal molar translation which results in full correction to a Class I molar relationship.

There are several additional benefits for using Carriere Distalizer prior to Invisalign.

- First, the most difficult problem to correct in the malocclusion is addressed and corrected initially. Elastic wear is completed in the first phase of treatment, as elastics are usually not needed while wearing aligners in the second phase of treatment. This eliminates any question of whether the molar relationship will be fully corrected by the time the teeth are well aligned.
- Second, the distalizer has shown the ability to correct sagittal discrepancies beyond what can be achieved by using aligners and elastics alone. Thus, adding the Carriere Distalizer to the treatment protocol expands the number of patients that can be effectively treated with Invisalign.

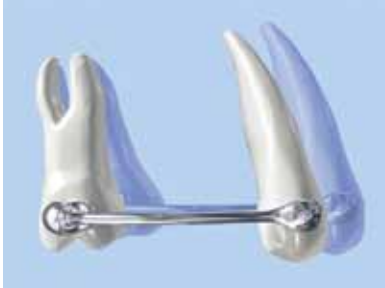- Third, the doctor has an early chance to measure patient compliance. If a patient fails to wear elastics for the short duration with the Carriere Distalizer, chances increase this patient will not demonstrate good compliance with the Invisalign treatment.
- Finally, treatment time is generally less as a result of the rapid correction of the molar relationship, which the patient can appreciate in the early stages of treatment.

Patient Selection for Carriere Distalizer

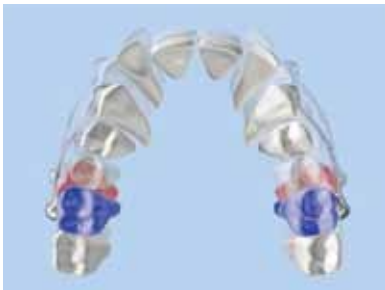
The distalizer is suitable for non-extraction patients where molar rotation alone will not correct the molar relationship to Class I molar. There should be a positive overbite at the start of treatment, in order to prevent an anterior open bite as a result of proclination of the lower incisors. The distalizer largely creates dental changes, with very little, if any, skeletal changes over the short duration of treatment. As such, the ideal patient presents with a minimal sagittal skeletal discrepancy between the maxilla and mandible, where the majority of the Class II relationship is the result procumbent maxillary incisors and maxillary first molars that are rotated mesially. The problems do not have to be bilateral, as the distalizer is amazingly effective at treating unilateral maxillary asymmetries. On the other end of the spectrum, full step Class II molar relationships with moderate to severe sagittal skeletal discrepancies would likely benefit more from an orthopedic type Class II correction appliance (Herbst, Twin Block, etc). In addition, growing patients tend to show faster, more consistent results with the distalizer. Consequently, adult treatment with the distalizer is not recommended.

¹ Ortho Organizers, Carlsbad, California

Phase I: Carriere Distalizer



Carriere Distalizer provides molar rotation and uprighting



Independently moves each posterior segment, from canine or premolar to molar, as a unit

The Carriere Distalizer comes in multiple sizes, spaced in 2 mm increments. Selection of the correct distalizer requires a measuring gauge and/or pretreatment models. The distalizer is directly bonded to the buccal surface of the first molar and either the maxillary cuspid or first bicuspid. The maxillary cuspid, when sufficiently erupted, is most often the tooth selected. To ensure maximum bonding strength, the distalizer is bonded with a hybrid filled restorative composite material.

Several options are available for the lower arch. A fixed lower lingual arch with bands on the lower first molars is modified by extending retention arms to either the second molars or lower first bicuspids. The benefit of the lower lingual arch is ease of use. All that will be required of the patient is placing and wearing elastics. Start with ¼", 4.5 oz upon appliance delivery. At the first 6 week visit, increase to ¼", 6.0 oz elastics and continue with these until full correction is achieved. A full coverage Essix type appliance can also be used on the lower arch to provide adequate lower arch stabilization.

Carriere to Invisalign Transition

Upon achieving full Class I molar correction, the Carriere Distalizer is removed from the maxillary arch along with the lower stabilizing device. PVS impressions are made immediately and in-house essix retainers are fabricated for both arches. The essix holding appliances may be worn at night only to adequately maintain the tooth positions prior to starting clear aligner treatment. The PVS impressions may be rinsed, sanitized, and sent in the records box to be used for fabrication of the aligners, or a digital scan could be made and transferred digitally.

Phase II: ClinCheck® Treatment Plan

Aligners effectively close the small spaces often present around the maxillary anterior teeth. Taking a panoramic x-ray following removal of the distalizer will provide specific details on root movement corrections that need to be verified in the ClinCheck treatment plan. Attachment design is important and there are some basic principles. Always keep and use Optimized Attachments whenever possible. In all instances, Optimized Attachments are the best available for the crown and root movement depicted in the ClinCheck treatment plan. If Optimized Attachments are located on upper cuspids, then the first bicuspids make a reasonable location for Precision Cuts.

While Class II elastics are not indicated in many cases following distalizer completion, it doesn't hurt to plan for their addition should the need arise. Retention attachments, 4x2x1 mm horizontal beveled attachments or similar, are usually requested on one molar in each quadrant. When a Precision Cut hook is added to a lower molar, a 4x2x1 retention attachment is added to the tooth mesially per Align's protocol—this will only happen if the lower molar does not have any other attachment. These attachments are required to maintain aligner stability when wearing any Class II elastics. In addition, poor or loose fitting aligners will not be worn as much as well-fitting, retentive aligners, thus decreasing the overall treatment effectiveness.

A final, but important ClinCheck factor involves posterior vertical changes. Molar teeth, especially upper second molars, should not be extruded. **A great advantage of Invisalign treatment is the ability to limit the passive vertical eruption of the molar teeth. In growing patients this can translate into a counter-**

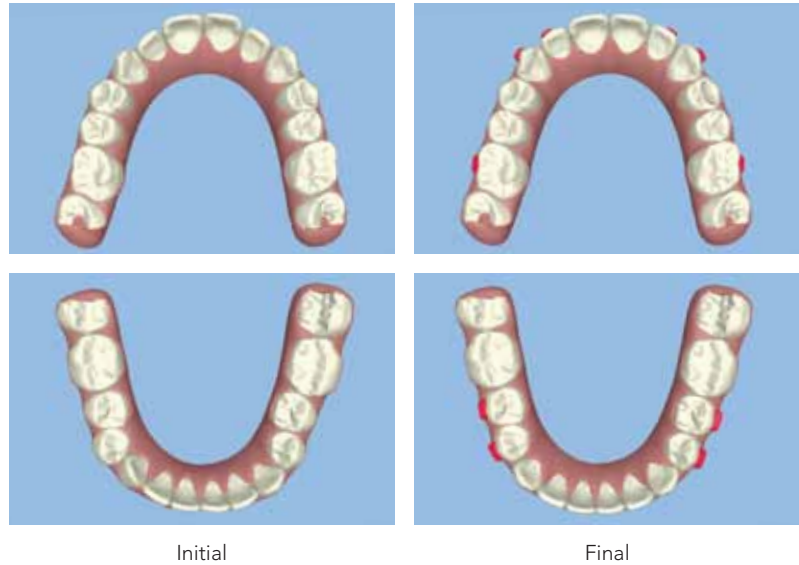
clockwise rotation of the mandible and enhance the sagittal position of the mandible. This is a big plus trying to maintain the molar relationship that was established by the Carriere Distalizer in the first phase of treatment.

The retention protocol following the second phase of treatment consists of placing a bonded lower lingual retainer and a maxillary full coverage Vivera or Essix-type thermoplastic retainer. The upper retainer is worn full time for 90 days, then nights only from that point on.

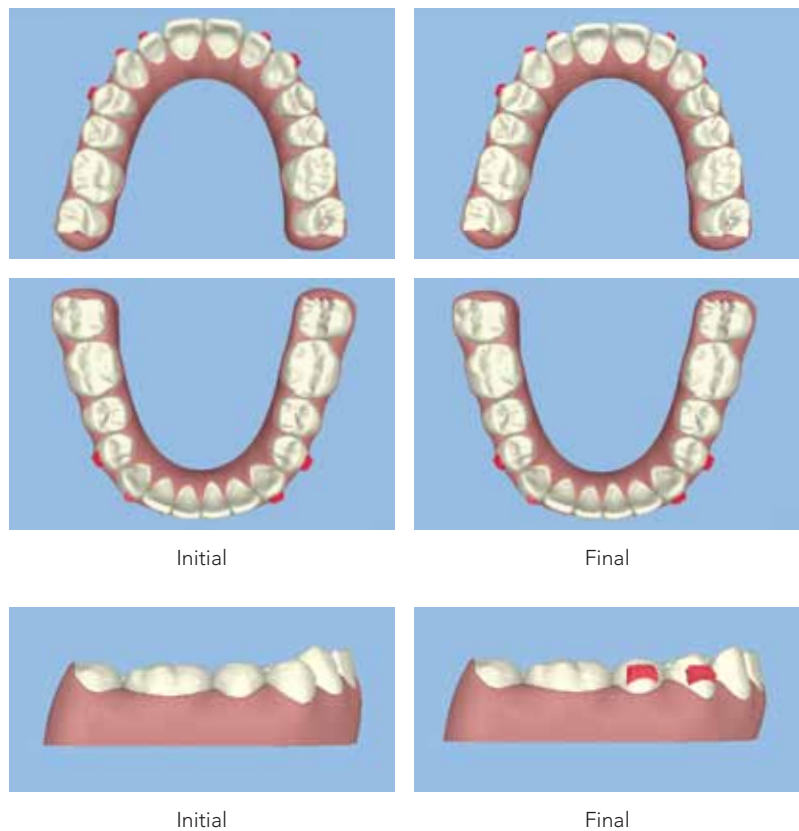
Patient Management Tips

Adequate explanation of the benefits of combination treatment requires patient education prior to starting treatment. When the patient and parent(s) understand how each appliance functions, then they buy-in to the rationale for combination treatment. Patients are asked if they would prefer wearing elastics with the Carriere Distalizer for the first 4 months of treatment to correct the most difficult part of their treatment, as opposed to wearing Invisalign and elastics for the entire treatment. Invariably, this puts things in perspective and they understand the efficiency and effectiveness gained by using the combination approach with the Carriere Distalizer. More importantly, the patient begins to accept ownership and responsibility for the success of their treatment. Their cooperation is the key to achieving the best possible result.

Initial Clincheck Treatment Plan



Refinement Clincheck Treatment Plan



Disclosure: Dr. Clark Colville was provided an honorarium from Align for his presentation. The statements, views and opinions expressed in this presentation are those of the author, and do not necessarily reflect the views and opinions of Align Technology, Inc.

Align Technology, Inc.
2560 Orchard Pkwy
San Jose, CA 95131

WWW.INVISALIGN.COM

© 2012 Align Technology, Inc. All rights reserved. Invisalign and ClinCheck, among others, are registered trademarks of Align Technology, Inc.
August 2012 M20227

